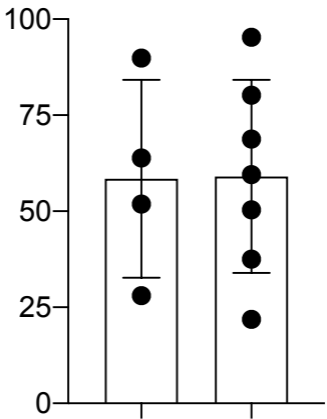


% Leukocytes in Tumor Biopsy



Low Grade

Moderate and High Grade